Check for updates

Circulation Research

PERIPHERAL VASCULAR DISEASE COMPENDIUM

Advances in Lymphedema

Stanley G. Rockson

ABSTRACT: Lymphedema is a common, complex, and inexplicably underappreciated human disease. Despite a history of relative neglect by health care providers and by governmental health care agencies, the last decade has seen an explosive growth of insights into, and approaches to, the problem of human lymphedema. The current review highlights the significant advances that have occurred in the investigative and clinical approaches to lymphedema, particularly over the last decade. This review summarizes the progress that has been attained in the realms of genetics, lymphatic imaging, and lymphatic surgery. Newer molecular insights are explored, along with their relationship to future molecular therapeutics. Growing insights into the relationships among lymphedema, obesity, and other comorbidities are important to consider in current and future responses to patients with lymphedema.

Key Words: ion channel ■ lymph ■ lymphatic vessels ■ lymphedema ■ obesity

Downloaded from http://ahajournals.org by on December 4, 2024

Lymphedema is a common, complex, and inexplicably underappreciated human disease.[1–5] Despite a history of relative neglect by health care providers and by governmental health care agencies, the last decade has seen an explosive growth of insights into, and approaches to, the problem of human lymphedema. As a point of reference, the number of articles in the National Library of Medicine indexed under the term lymphedema from 2001 to 2010 was 3285; within the last decade, that number has more than doubled.

The current review will attempt to highlight the significant advances that have occurred in the investigative and clinical approaches to lymphedema, particularly over the last decade. This review will summarize the progress that has been attained in the realms of genetics, lymphatic imaging, and lymphatic surgery. Newer molecular insights will be summarized, along with their relationship to future molecular therapeutics. Growing insights into the relationships among lymphedema, obesity, and other comorbidities will be highlighted.

GENETICS

Conventionally, lymphedema has been considered, in a binary schema, as a presentation of either primary or secondary disease. While this is likely an oversimplification,[6] it does permit the distinction among the attributes of so-called secondary lymphedema, which represents the functional consequences of an insult to a previously normal vascular conduit system,[2,4] with those that, in the primary form of the disease, reflect inborn errors in the structure or function of the lymphatic vascular system, even if the lymphatic dysfunction is not detectable at birth. At present, there are 28 known genes that might harbor causal mutations for primary lymphedema, yet these identified mutations account for <30% of the identified case presentations.[7] Given the central role of VEGF-C (vascular endothelial growth factor C)/VEGFR3 (vascular endothelial growth factor receptor 3) interactions in the normal development of the lymphatics, it is not surprising that several of the identified responsible mutations reside within genes that encode proteins that are active in this pathway, including VEGFR3, VEGFC, CCBE1 (collagen and calcium-binding epidermal growth factor [EGF] domains 1), and ADAMTS3 (ADAM metallopeptidase with thrombospondin type 1 motif 3).[8] Mutations affecting either VEGF-C or VEGFR3 typically provoke a congenital presentation of either regional or more widespread lymphedema,[9–11] while CCBE1 and ADAMTS3 disturbances are

Correspondence to: Stanley G. Rockson, MD, Allan and Tina Neill Profess of Lymphatic Research and Medicine, Stanford University School of Medicine, Stanford, California 94305. Email rockson@stanford.edu

For Disclosures, see page 2012.

© 2021 American Heart Association, Inc.

Circulation Research is available at www.ahajournals.org/journal/res

Nonstandard Abbreviations and Acronyms

5-LO	5-lipoxygenase
ADAMTS3	ADAM metallopeptidase with thrombospondin type 1 motif 3
ARM	axillary reverse mapping
CCBE1	collagen and calcium binding EGF domains 1
EPHB4	ephrin B4
FAT4	FAT tumor suppressor homolog 4
FOXC2	forkhead box C2
GJC2	gap junction protein Gamma 2
LTB4	leukotriene B4
MR	magnetic resonance
NIR	near-infrared
PIEZO1	Piezo type mechanosensitive ion channel component 1
TIE	tyrosine kinase with immunoglobulin like and EGF like domain
VEGF-C	vascular endothelial growth factor C
VEGFR3	vascular endothelial growth factor receptor 3
VLNT	vascularized lymph node transfer

responsible for various presentations of the Hennekam syndrome,[12,13] which can feature intestinal lymphangiectasia and other mesenteric lymphatic abnormalities along with the presenting generalized lymphedema. Others of the identified primary lymphedema mutations (EPHB4 [ephrin B4], FOXC2 [forkhead box C2], GATA2 (GATA-binding factor 2), PIEZO1 [Piezo type mechanosensitive ion channel component 1], GJC2 [gap junction protein gamma 2], and FAT4 [FAT tumor suppressor homolog 4]) encode proteins that play an active role in the maturation and remodeling of the nascent lymphatic circulation.[8] For several of these mutations, the phenotypic presentations suggest that the pathogenesis of lymphedema entails structural or functional derangement of the lymphatic valvular apparatus.[14–19] One of the most recently identified genetic causes for primary lymphedema entails functional missense mutation that has a dominant-negative effect on angiopoietin2 signaling.[7] In lymphatic endothelium, angiopoietin 2 functions as autocrine agonist of TIE (tyrosine kinase with immunoglobulin like and EGF-like domains 1) 1 and TIE2 and, thus, loss of function mutations or haploinsufficiency of this gene can contribute to the phenotypic expression of primary lymphedema. This most recent discovery is illustrative of the current experience with the identification of causal mutations in primary lymphedema: while no targeted therapeutic intervention has yet emanated from these discoveries, much has been learned about pathways of normal lymphatic development and maintenance that, in future, will invest diagnostic and therapeutic approaches to these specific cohorts and, to a degree, to lymphedema in general.

Primary lymphedema, and lymphedema in aggregate, can have a very heterogeneous presentation. Rigorous phenotyping of lymphatic patients has increasingly permitted a molecular basis for diagnosis.[8,20] A clinically useful algorithm for the genotype/phenotype relationships in primary lymphedema has been proposed (Figure 1).[20] An optimistic yet realistic expectation might be that such careful analysis will soon lead to the development of novel and targeted molecular therapies.

It is likely that lessons derived from studies of primary lymphedema will also invest our comprehension of the pathogenesis of acquired lymphedema. Inasmuch as the treatment-related risk factors for cancer-associated lymphedema do not fully predict the stratification to lymphedema-positive and -negative cancer survivorship,[2,4] it is entirely plausible that the predisposition to secondary lymphedema is dependent upon genetically endowed features that influence, for example, the lymphatic regenerative response to injury.[6]

IMAGING

Historically, imaging of the lymphatics for clinical assessment has been limited, and less well developed than blood vascular imaging, typically having required tissue injection of detectable imaging agents within the regional compartments of the lymphatic circulation, representing a series of unidirectional vascular conduits.[21] The limited ability to visualize the anatomy and function of the lymphatic system has, in turn, hampered development of diagnostic and therapeutic approaches in lymphedema and other lymphatic disorders.

The modern era of lymphatic imaging was initiated in 1955 by Kinmonth, when he introduced direct contrast lymphography into the clinical lexicon. While this technique permits visualization of the deep lymphatic structures (Table 1), it has virtually disappeared from clinical use as historically practiced, because the 2-step technique (peripheral lymphatic visualization with vital dyes, followed by direct surgical cannulation) is cumbersome and very time-consuming. The inability to efficiently image the lymphatics through direct cannulation has led to the development of a variety indirect imaging techniques.

Lymphoscintigraphy and Single-Photon Emission Computerized Tomography/ Computed Tomography

Radionuclide lymphoscintigraphy (Figure 2A) is generally accepted as the gold standard for clinical lymphatic imaging.[22] The method entails introduction into the tissues, by

Downloaded from http://ahajournals.org by on December 4, 2024

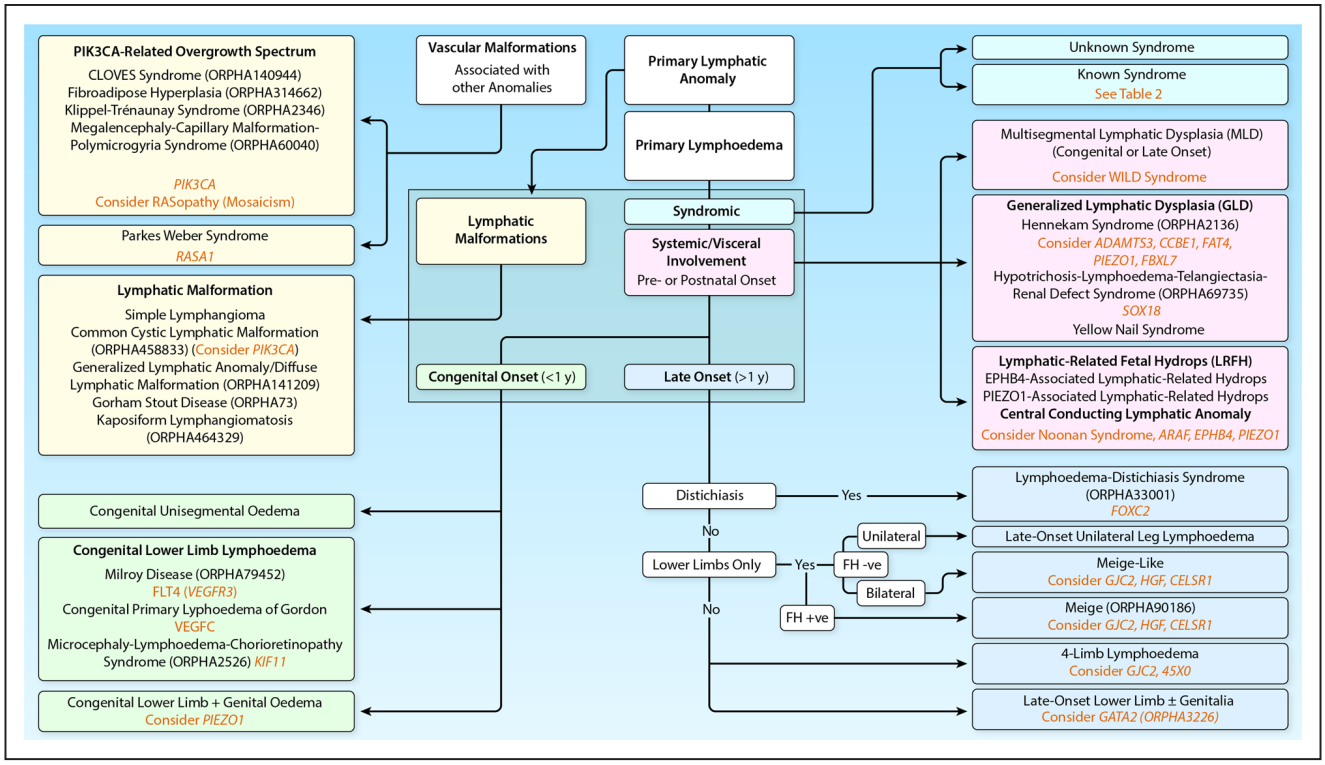

Figure 1. St. George's classification algorithm for the diagnostic and genetic evaluation of primary lymphatic anomalies.
Illustration credit: Ben Smith. This figure has been modified from Gordon et al.[20,58]

injection, of a tracer-labeled large molecule; imaging of the emitted signal with a gamma camera permits characterization of lymphatic transport function.[23] While lymphoscintigraphy provides poor spatial and temporal resolution and lacks standardization,[22] it has high reported sensitivity (96%) and specificity (100%) for the diagnosis of lymphedema.[24] Although lymphoscintigraphy can be used for disease staging in lymphedema, the technique remains generally hampered by protocol variability and poor image resolution.[25] Nevertheless, in primary lymphedemas, the imaging results can be helpful in phenotyping of patients (Figure 1).

Quantitative and semi-quantitative analysis of lymphatic function is feasible through scintigraphy, yet the technique does not provide substantial anatomic information. More recently, it has become feasible to enhance the diagnostic functionality of scintigraphy through combination with radiographic tomography (single-photon emission computerized tomography/computed tomography).[26] Radiographic tomography (computed tomography) without single-photon emission computerized tomography can also provide some diagnostic insights: honeycomb appearance and alterations in the morphology of the fat lobules are characteristic, but not absolutely diagnostic, of lymphedema.[27]

Near-Infrared Lymphography

Near-infrared lymphography (NIR, Figure 2B) is a relatively more recently introduced approach that has proven to be clinically useful,[28] particularly in surgical contexts. In preclinical animal model systems, NIR provides visualization and quantifiability of collecting lymphatic vessel function.[29] In analogy to lymphoscintigraphy, NIR requires tissue introduction of the fluorescent dye, in this case through intracutaneous injection. In current human medical applications, NIR relies upon the availability of indocyanine green, a Food and Drug Administration-approved molecule that possesses the requisite near-infrared fluorescence characteristic. In vivo, the injected indocyanine green binds both to albumin and to lipoproteins,[22] thereby acquiring the requisite size requirements for obligatory lymphatic clearance. With microgram-range dosing, the superficial lymphatic structures can be visualized in the skin at a depth of 1.5 cm (Table 1).

With high penetration and low-light scatter, NIR lymphography provides enhanced opportunities to define superficial lymphatic anatomy, including more precise, quantitative analysis of collecting vessel contractility.[30–32] The advantages over standard radionuclide lymphoscintigraphy are most apparent in the realm of dermal backflow assessment: the enhanced discrimination of patterns of backflow with NIR has facilitated the elaboration of grading schemata that correlate with lymphedema natural history and characterize the severity of the disease,[33,34] with demonstrable utility in detecting preclinical disease in the setting breast cancer-associated risk.[33] Lymphatic function can be defined as normal or abnormal[35]; subcategories for the latter include progressive

Downloaded from http://ahajournals.org by on December 4, 2024

Table 1. Clinical Imaging for Lymphedema. Modified From Polomska and Proulx[22]

Technique	Lymphatic application	Resolution	Depth limitation
Contrast lymphography	Central/visceral lymphatic visualization	≈1 mm	No limit
Radionuclide lymphoscintigraphy	Imaging of collecting lymphatic vessels and dermal backflow; quantitative assessment of lymphatic function	≈1.5 mm	No limit
Near infrared lymphography	Imaging of collecting lymphatic vessels and dermal backflow; quantitative assessment of lymphatic function	µm range	1.5 cm
MR lymphography	Central/visceral lymphatic visualization; functional and morphological evaluation of lymphatic vessel status	0.5–2 mm	No limit
CT	Assessment of lymphatic vessel status	50–200 µm	No limit
SPECT	Assessment of lymphatic vessel status	1–2 cm	No limit

CT indicates computed tomography; MR, magnetic resonance; and SPECT, single-photon emission computerized tomography.

degrees of dermal backflow, from so-called stardust to diffuse patterns. The most severe manifestations are defined no flow, with failure to discriminate migration of the indocyanine green from the depot injection.[33]

NIR lymphography has proven to be particularly useful in relationship to the increasingly employed surgical interventions for lymphedema,[36] such as, for example, the decision to resort to lymphaticovenular anastomosis.[34] In addition to surgical triage, the technique is applied for the presurgical identification of lymphatic vasculature.[37,38] Furthermore, NIR lymphography can be employed to assess lymphatic flow in the context of free flap transplants and vascularized lymph node transfer (VLNT).[39]

NIR lymphography has also been proposed as a diagnostic method to guide and personalize the conservative management techniques in lymphedema, through the identification of compensatory drainage pathways.[40] This can be potentially useful in both primary and secondary lymphedemas. Nevertheless, despite its demonstrated utility in various clinical settings, NIR lymphography has inherent limitations, largely conferred by the imperfect nature of indocyanine green as an imaging agent. Its use in intracutaneous injection remains off-label, and the agent is by nature unstable and self-quenching[22]; it can be anticipated that the development of newer, more targeted agents[41,42] will enhance the applicability of near-infrared imaging for lymphatic medicine.

MAGNETIC RESONANCE LYMPHOGRAPHY

Diagnostic evaluation for lymphedema is feasible through magnetic resonance (MR) imaging without contrast enhancement.[43–46] In this approach, heavily T2-weighted sequencing is used to enhance the signal emitted by the expanded fluid volume within the lymphatic vasculature while simultaneously suppressing tissue signaling. Tissue anatomic changes can simultaneously be visualized[47] (Figure 2C), and the characteristic distribution of edematous changes within the adipose compartment reportedly can assist in distinguishing lymphatic from venous etiologies.[45]

Contrast-enhanced MR lymphography can be performed either dynamically, as an alternative to the historical direct contrast approach by X ray, or through techniques analogous to radionuclide or NIR lymphography. In the latter approach, interstitial injection of the T1-weighted, gadolinium-based contrast agent is accomplished, thereby facilitating the visualization of both dilated lymphatics and dermal backflow, along with the soft tissue derangements that are directly attributable to the attendant lymphedema.[48] This approach has proven particularly useful in the perioperative evaluation for lymphatic microsurgery.[49–51] For dynamically acquired lymphography, which provides visualization of central structures such as the cisterna chyli and the thoracic duct, there is intranodal injection of the gadolinium compound through ultrasonic guidance, with subsequent T1-weighted imaging.[52] In addition to enhanced lymphatic specificity, such approaches facilitate catheter-based therapeutic interventions, such as thoracic duct embolization, for patients in whom peripheral lymphedema accompanies defects of the central conducting channels, including chylous effusions and protein-losing enteropathy.[53] Such findings are particularly relevant to the primary lymphedema population.

MR lymphangiography, in its current iterations, provides distinct advantages over lymphoscintigraphy and NIR lymphography, including better imaging depth limits and the capability of 3-dimensional volumetric imaging, but venous signal enhancement is a theoretical drawback, and the MR techniques continue to be limited by the absence of lymphatic-specific tracers and the high costs associated with MR imaging.[22]

HIGH-FREQUENCY ULTRASOUND

Historically, ultrasound has had relatively less applicability to the clinical evaluation of lymphedema, but the technique does have the capacity to characterize the dermal thickening and hypoechogenicity that is associated with disease, and may be useful to differentiate lymphedema from lipedema.[54] In addition, more recently, the utility of ultra-high frequency ultrasound has been demonstrated for the pre- and intraoperative visualization of lymphatic channels.[55]

Downloaded from http://ahajournals.org by on December 4, 2024

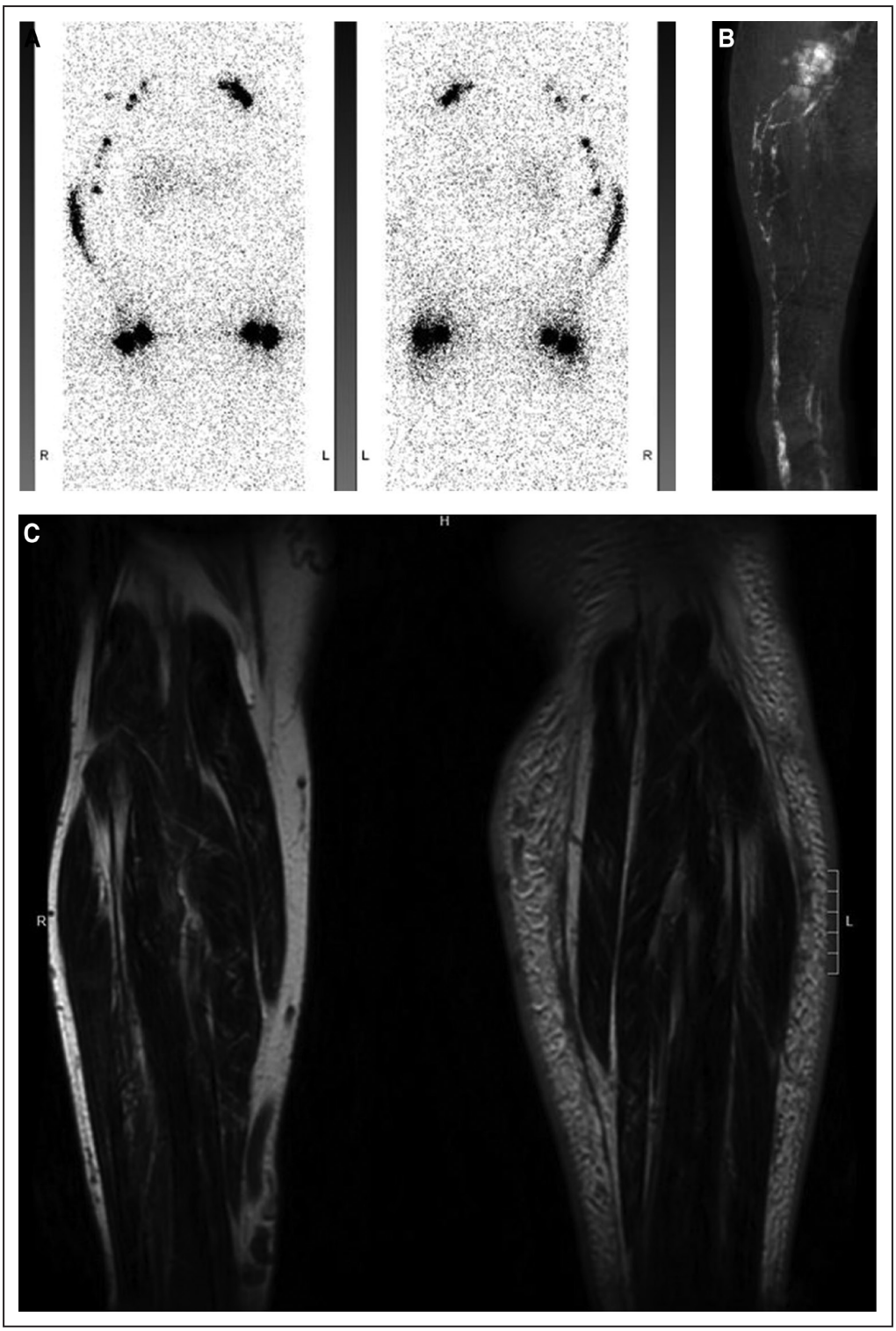

Figure 2. Imaging of peripheral lymphedema.
A, Upper extremity radionuclide lymphoscintigraphy demonstrates findings compatible with right arm lymphedema, including diminished nodal uptake of radiotracer and prominent dermal backflow. **B**, Near-infrared lymphography of the lower extremity defines lymphatic collectors and demonstrates dermal backflow (courtesy of Dr Peter Neligan). **C**, Magnetic resonance imaging of the leg demonstrates the typical lymphedematous changes of edema and subcutaneous adipose hypertrophy in the affected left leg.

LYMPHATIC SURGERY

The last decade has witnessed a substantial upsurge in the utilization of surgical interventions for patients with lymphedema. These interventions can be divided into 3 broad categories: procedures designed to reduce the likelihood of lymphedema, debulking operations, and microsurgical interventions to correct impaired lymphatic vascular function.

Downloaded from http://ahajournals.org by on December 4, 2024

Surgical Prevention of Lymphedema

Axillary reverse mapping (ARM) is a presurgical technique that is designed to protect the lymphatic drainage pathways of the ipsilateral arm at the time of surgical intervention for breast cancer.[56] Building upon well-established intraoperative lymphatic mapping of the breast lymphatics, the ARM technique entails a split mapping procedure, with use of radionuclide tracers for the breast sentinel node identification and vital dyes, such as isosulfan blue, for identification of the sentinel node draining the upper extremity. The blue-stained lymph nodes can be surgically avoided unless they also have crossover radiotracer activity that necessitates their removal. In the initial description of this procedure, ARM identified substantial lymphatic variability and facilitated preservation of the arm lymphatic drainage in all but one of the studied patients.[56] Crossover nodes are uncommon, described in 3.8% of sentinel lymph node biopsies and 5.6% of axillary lymph node dissections.[57] One prospective study of 265 patients documented a reduction of lymphedema incidence, from 33% in the control group to 6%, in the experimental ARM group.[58] The oncological safety of the ARM approach has been questioned[59]; prospective studies remain underway to assess the efficacy and oncological safety of the ARM approach.[60]

The lymphatic microsurgical preventive healing approach was introduced in 2009.[61] Performed at the time of axillary lymph node dissection, it intends to reduce the likelihood of subsequent ipsilateral arm lymphedema through the concurrent creation of a preemptive lymphatic-to-vein anastomosis.[2] An early, single-institution experience, and 6-month mean follow-up, provided evidence of a substantially reduced incidence of lymphedema.[62] More recent, prospective evaluation of the impact of the lymphatic microsurgical preventive healing approach suggests that it creates a significantly lower risk of lymphedema when compared with standard axillary lymph node dissection (3% versus 19% over a median follow-up of 15 months).[63]

Surgical Volume Reduction

Suction-assisted protein lipectomy is a surgical intervention that is designed to address the progressive hypertrophy of the subcutaneous adipose tissue that inevitably accompanies chronic lymphedema.[2] Brorson and Svensson[64] introduced the concept of combined liposuction and compression therapy in 1998. In those patients in whom limb volume or size poses functional problems, or to enhance the responses to conservative therapy, nearly 100% removal of excess limb volume can be accomplished through the surgical use of specialized cannulas under general anesthesia.[65] This approach has been documented to provide sustained volume reduction for >15 years of patient follow-up,[65] along with reduction in the incidence of soft-tissue infections after the procedure.[66,67] Suction-assisted protein lipectomy alone is not sufficient; compliance with postoperative high-grade compression regimens is essential.[68] Suction-assisted protein lipectomy does not exacerbate lymphedema or further damage the lymphatic vasculature.[67]

Microsurgical Interventions

The evolution of lymphatic micosurgical techniques has facilitated the evolution of physiological surgical interventions for the amelioration of lymphedema, including lymphaticovenous anastomosis and VLNT.[69]

Lymphaticovenous anastomosis is a surgical approach in which NIR lymphography permits the minimally invasive identification of patent lymphatic vasculature, facilitating anastomosis to adjacent venous structures.[70,71] Since the success of the procedure relies upon residual partial lymphatic function and minimal fibrosis,[69] it has its greatest potential impact in early lymphedema.[72]

Lymphaticovenous anastomosis has demonstrated efficacy for both primary[73] and secondary lymphedema,[74] including amelioration of limb volume, symptomatology, and quality-of-life[75–77]; however, symptomatic improvement is less commonly achieved in lower extremity lymphedema.[75] An average, estimated 57% reduction in excess limb volume has been observed in meta-analysis, representing a mean absolute volume reduction of 23.6%[78]; reported rates of successful compression garment discontinuation approach 85%.[76] Reported typical complications include cellulitis, lymphorrhea, and the need for additional procedures.[75] The chief current disadvantage of lymphaticovenous anastomosis is the limitation in availability of data regarding long-term patency of these anastomoses.

VLNT entails tissue transfer of lymphatic tissue, with its vascular supply, as a donor flap to the lymphedema-affected limb. Potential donor sites for lymphatic tissue include supraclavicular, submental, lateral thoracic, and inguinal nodes,[79] along with omental[80] and jejunal[81] donor sites.

The mechanism of therapeutic benefit from VLNT has not been established. One theory suggests that the transplanted lymphatic tissue serves a pumping mechanism to transfer interstitial fluid to the efferent circulation.[82] Alternatively, it is believed that the donor tissue serves as an abundant source of lymphangiogenic growth factors that can mediate lymphatic vascular repair.[72,83,84] This latter concept can be supported through indirect observations in preclinical animal models.[85]

While the therapeutic effect of VLNT cannot yet be ascribed to a distinct mechanism, the procedure provides salutary effects in human lymphedema. One prospective, randomized study of VLNT for breast cancer lymphedema demonstrated a significantly greater reduction in limb volume (57% versus 18%) when VLNT was added to conservative measures.[86] The authors also documented improved symptomatology and reduction

Downloaded from http://ahajournals.org by on December 4, 2024

in the incidence of cellulitis. Nonetheless, the aggregate paucity of prospectively acquired data[87] suggests that continued investigation of this therapeutic modality will be mandatory. A decision to pursue VLNT will entail consideration of potential adverse responses, which include lymphocele, wound healing complications, and, of greatest concern, donor site lymphedema.[69,88] It has been suggested that potential concern for donor site lymphedema can be minimized through reverse lymphatic mapping[89] or the use of mesenteric donor sites.[81]

Combination therapy has been proposed for each of the surgical elements heretofore discussed, including the option of combining VLNT with breast reconstruction. The relative potential benefits and limitations of lymphedema surgical options are summarized in Table 2. In summary, it should be noted that current assessments regarding the potential benefit of surgical intervention may be limited by their largely single-center origin and the inherent potential bias to favor intervention.

INSIGHT INTO MOLECULAR MECHANISMS AND THE PATH TO MOLECULAR THERAPIES

The lymphatic vasculature is responsible for the volume and composition of fluid in the intercellular space. Thus, conventional mechanistic thinking about lymphedema has emphasized the loss of interstitial fluid homeostasis that leads to the development and persistence of chronic edema and, accordingly, therapeutic approaches have fundamentally attempted to address these phenomena mechanically and, more recently, surgically. Newer insights into the molecular pathogenesis and natural history of lymphedema have centered on the important mechanisms of chronic inflammation and fibrosis; in addition, because lymphedema arises either from faulty lymphatic development or insufficient repair of secondary insults to the vasculature, there has been ongoing interest in the molecular machinery that can drive or augment lymphangiogenesis and regeneration.

Table 2. Potential Benefits and Limitations of the Surgical Interventions for Lymphedema

Intervention	Potential benefits	Potential limitations
ARM	Preserves the arm sentinel node and may prevent breast cancer-related lymphedema	Oncological safety is not completely established
LYMPHA	May preemptively prevent breast cancer-related lymphedema	Lengthens the operative time for axillary lymph node dissection
		May require multiple surgical teams
SAPL	Restores limb volume and function in chronic lymphedema	Requires long-term patient compliance with a stringent compression regimen following the procedure
		Not optimally effective if hydrostatic edema is not well-controlled before surgery
LVA	Minimally invasive	Variable success rate
	Rapid recovery	Durability of the surgical response may be variable
		Not feasible in later stages of lymphedema if vascular channels are not amenable to surgical anastomosis
VLNT	Can potentially restore both circulatory and immune lymphatic function	More invasive with longer anesthesia times
		Risk of donor site lymphedema
	Feasible in later, more advanced stages of lymphedema	Variable success rate

ARM indicates axillary reverse mapping; LVA, lymphaticovenous anastomosis; LYMPHA, lymphatic microsurgical preventive healing approach; SAPL, suction-assisted protein lipectomy; and VLNT, vascularized lymph node transfer.

Lymphangiogenesis

As we have seen previously, the VEGF/VEGFR3 axis is central to the process of embryonic lymphatic development and, by extension, the postnatal lymphangiogenesis, the process of postembryonic lymphatic growth and repair. Given the pivotal role of this molecular axis in the normal biological processes, there has been longstanding interest in harnessing the power of these signaling mechanisms to stimulate lymphatic repair therapeutically.

Preclinical animal models of acquired lymphedema lend support for therapeutic lymphangiogenesis through VEGF-C/VEGFR and various other lymphangiogenic growth factor signaling pathways.[90–98] However, as in many other contexts related to therapeutic lymphangiogenesis, the complexity of the repair response is difficult to harness. Overexpression of VEGF-C in the skin may stimulate lymphatic vessel hyperplasia in the absence of augmented functionality.[99] In addition, data derived from transgenic mice and in a hindlimb acquired lymphedema model support the observation that endogenous VEGF-C can actually exert an exacerbating effect on lymphedema through enhanced vascular leakage,[100] further complicating notions of growth factor-mediated therapeutic lymphangiogenesis. In addition, the application of growth factor therapy for lymphedema should be theoretically constrained with the acknowledgment that these same growth factors participate in the creation of tumor microenvironments and may thereby encourage the accelerated growth of micrometastases in cancer survivors with lymphedema.[101]

Of note, the safety of combined lymph node transfer and administered adenoviral VEGF-C has been established in a small breast cancer-associated lymphedema trial[102]; the therapeutic impact of both VEGF-C and hepatocyte growth factor (HGF) are under current investigation.

Stem Cell Therapy

Stem cell therapy represents a potential future alternative to direct therapeutic administration of growth

Downloaded from http://ahajournals.org by on December 4, 2024

factors in lymphedema. Two prospective human clinical studies of autologous bone marrow-derived mesenchymal cells have demonstrated modest therapeutic efficacy in breast cancer-related lymphedema.[103,104] More recently, an isolated case report of administration of freshly isolated, autologous, adipose-derived stromal cells combined with a fat graft in breast cancer-related lymphedema apparently provoked volume reduction accompanied by subjective improvement.[105] There were no reported adverse effects.

The potential beneficial mechanism(s) of stem cell therapy have not been firmly established for lymphedema, yet it is established that these mesenchymal cells have the capacity to differentiate into cells with lymphatic endothelial properties in vitro.[106] These cells acquire both the phenotype and molecular expression profile of lymphatic endothelial cells and, in a preclinical lymphedema model, seem to improve lymphatic drainage after injection.[106] These observations have not, however, been extended to human clinical observations.

The Role of Chronic Inflammation

Postfilarial lymphedema represents a prototype for the role of inflammation in the pathogenesis and maintenance of lymphatic dysfunction (summarized in Jiang et al[107]), suggesting that both innate and adaptive immune mechanisms participate in the development of lymphedema after the initial insult. While the cellular and cytokine inflammatory responses of filariatic lymphedema are exuberant, it would appear that many of the same component mechanisms participate in other forms of acquired disease, such as the cancer-associated form of lymphedema that is commonly encountered in the developed world.[107] In preclinical models of acquired lymphedema, the skin demonstrates infiltration of dendritic cells, CD4+ T cells, macrophages, and neutrophils, albeit to a lesser degree than in filariasis. Depletion of CD4+ T cells, but not CD25+ Treg cells, significantly decreases lymphedema, inflammation, fibrosis, and adipose tissue deposition, which suggests that non-Treg CD4+ T cells is central to lymphedema pathogenesis.[108]

The transcriptional expression profile of lymphedematous skin has a prominent inflammatory signature including, notably, upregulation of the expression of 5-LO (5-lipoxygenase).[109] Accordingly, ketoprofen (a nonsteroidal anti-inflammatory drug that uniquely inhibits 5-LO along with cyclooxygenase inhibition) has the capacity to reverse experimental, acquired murine lymphedema, and to ameliorate the associated cutaneous histopathology, while TNF-α (tumor necrosis factor-alpha) inhibition exacerbates these same features.[110] These ameliorative responses in clinically measured skin thickness and cutaneous histopathologic changes in response to oral ketoprofen therapy have subsequently been confirmed in a pilot, prospective, placebo-controlled human study.[111] In this trial, the clinical responses were limited to an improvement in the structural integrity of skin, while statistically significant changes in limb volume or bioimpedance were not observed. The study suggests promise in the future investigation of this and similar pharmacological approaches.

These observations have prompted further investigation of the role of prostaglandins and leukotrienes in the pathogenesis of lymphedema,[112] given the potential involvement of 5-LO activation in the disease. Of note, ibuprofen, a cyclooxygenase inhibitor that lacks 5-LO inhibitory capacity, exacerbates the edema response in the experimental model. This suggests that the cyclooxygenase-generated prostaglandins may simultaneously play a protective role. However, pharmacological interrogation of the 5-LO pathway consistently suggests that inhibition of LTB4 (leukotriene B4, a downstream product of 5-LO activation), but not the cystineinyl leukotriene pathway, can reverse edema and improve lymphatic vascular function.[112] LTB4 promotes lymphedema development through a variety of properties, including inhibition of VEGFR3 mRNA expression and protein phosphorylation, inhibition of Notch signaling (a pathway important for lymphatic development and maintenance[113]), and reduced macrophage, neutrophil, and CD4+ T-cell infiltration into the lymphedematous tissues.[112] Finally, serum LTB4 levels have been demonstrated to be elevated in human patients with lymphedema. It should be noted that pharmacological antagonism of LTB4 production in human lymphedema was attempted with ubenimex in a pilot clinical investigation, but the trial was vastly underpowered to assess the primary clinical end point (unpublished observations); therefore, the promising efficacy of LTB4 antagonism in experimental lymphedema remains to be established in the human disease.

In aggregate, prior observations suggest that further investigation of inflammatory mechanisms in lymphedema will be fruitful, and that there is potential for pharmacological anti-inflammatory interventions to ameliorate the expression of the disease.

Fibrosis

Within the natural history of lymphedema, the lymphatic vasculature is progressively invaded by fibrosis, with luminal obliteration and loss of function.[114] As previously discussed, depletion of CD4+ T cells significantly decreases lymphedema, inflammation, fibrosis, and adipose tissue deposition in lymphedema. Depletion of CD4+ cells prevents disease development.[115] These findings parallel the observation that, through enhancement of TGF-β (transforming growth factor-beta) signaling, the Th2 immune response plays a role in the development of the fibrosis that seems to inevitably accompany lymph stasis.[116] Furthermore, blockade of Th2 differentiation through anti-IL4 (anti-interleukin [IL] 4) or anti-IL13 antibodies reported has the capacity to reverse lymphatic fibrosis and improve lymphatic function.[117] A correlative finding is the fact that IL4 and IL13 can suppress lymphatic

Downloaded from http://ahajournals.org by on December 4, 2024

endothelial cell expression of LYVE-1 (lymphatic vessel endothelial hyaluronan receptor 1) and Prox1 (prospero homeobox protein 1) expression and impair lymphatic endothelial cell survival, proliferation, migration, and tube formation.[118,119] In addition, Th1, Th2, and Th17 cells have been demonstrated, in various model systems, to contribute to the fibrosis response of postsurgical lymphedema.[120,121]

Macrophages may also play an integral role in this process. Macrophages are present in the skin of both experimental lymphedema models and human lymphedema patients.[122,123] Macrophages apparently promote lymphedema development acutely, yet macrophage depletion, which does not diminish edema or adipose deposition, does promote tissue fibrosis. This enhanced tissue fibrotic response after macrophage depletion is perhaps thought to reflect increased consequent CD4+ cell accumulation and skewed Th2 differentiation.[121]

The Th1/Th2 paradigm in fibrosis suggests that these mechanisms play a causal role in the tissue fibrosis of lymphedema. In addition to the impact of the Th2 cytokines as discussed, along with the downstream reduction of TGF-β expression, it is feasible that Th2 cells further contribute to this process indirectly through the promotion of monocyte differentiation toward alternatively activated macrophages.[124] Beyond inhibition of IL4 and IL13, hyaluronidase may pose future therapeutic promise: in a preclinical murine hindlimb lymphedema model, challenge with hyaluronidase reversed fibrosis through enhanced Th1 and diminished Th2 cell activity.[125]

A contributory role for the previously discussed leukotriene, LTB4, in the pathogenesis of lymphedema-associated fibrosis has not yet been investigated, but it should be noted LTB4 has previously been recognized to activate fibroblasts in other organ systems.[126]

In summary, inflammation and fibrosis are intertwined, fundamental manifestations of lymphedema and pathogenesis and, therefore, represent dual targets for future investigation and human therapeutic intervention. The interplay among cells and potential molecular mediators of lymphedema pathogenesis is summarized in Figure 3.

OBESITY AND LYMPHEDEMA

While obesity has long been identified as a potential risk factor that predisposes to the development of acquired lymphedema in cancer survivors,[127] chronic lymphedema,

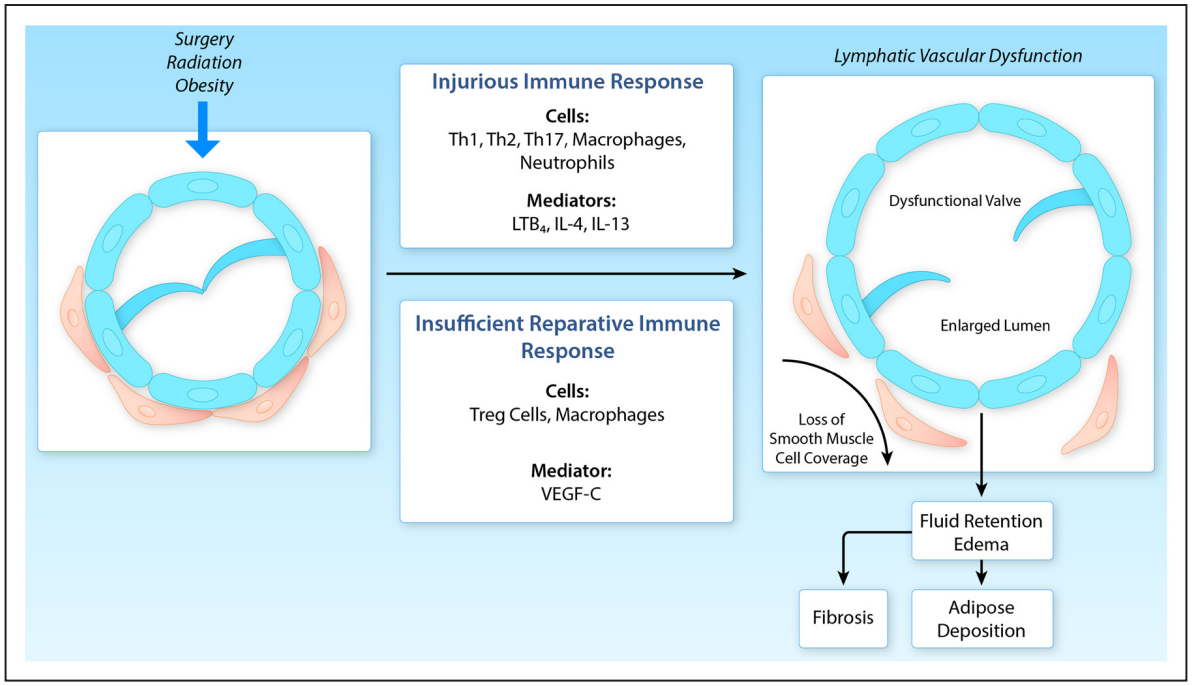

Figure 3. Pathophysiology of acquired lymphedema.
Lymphatic injury, caused by surgery, radiation, or obesity, induces an immune response that includes T helper (Th) 1-, Th2-, and Th17-mediated T-cell immunity, along with macrophage- and neutrophil-mediated innate immunity. IL indicates interleukin; LTB4, leukotriene B4; and VEGF-C, vascular endothelial growth factor-C. Illustration credit: Ben Smith. This figure has been modified from Jiang et al.[107]

Downloaded from http://ahajournals.org by on December 4, 2024

in parallel, commonly precipitates adipocyte hypertrophy.[65,128] This is a form of regional obesity, characterized by the abnormal growth of adipose tissue within the edema-affected zones of the body. The mechanisms through which adipose tissue deposition occurs in lymphedema are poorly understood. In murine acquired lymphedema models, lymph stasis activates adipocytes and upregulates fat differentiation genes, such as peroxisome proliferator-activated receptor γ and CCAAT/enhancer-binding protein α.[129,130] In addition to the adipose hypertrophy, the resulting inflammation can further provoke fibrosis.[129]

Additional insights into the pathogenesis of fat hypertrophy can be derived from genetically altered mouse models. In the heterozygous Chy mouse, for example, underdeveloped dermal lymphatics lead to the development of lymphedema, there is also fat deposition in the skin.[131,132] Adult-onset obesity is a feature of the heterozygous Prox1 haploinsufficient mouse. These mice have demonstrably defective and leaky lymphatic vessels both in the skin and, notably, in the mesentery, and chyle collected from these animals stimulates adipogenesis in vitro.[133] It appears that it is the free fatty acid content of lymph that stimulates adipogenesis; restoration of lymphatic vascular function in these mice rescues the obesity phenotype.[134]

There is evidence that obesity itself can be a precipitating cause of human lymphedema.[135–138] Mechanistic support for this observation can be derived from diet-induced, obese K14- VEGF-C mice, where adipose hypertrophy induces a functional impairment in the lymphatic collecting vasculature, with concomitant structural alterations.[139] In a model of diet-induced adiposity, obese mice have impaired baseline lymphatic function that is exacerbated by lymphatic injury and is accompanied by increased chronic inflammation, fibrosis, and adipose deposition.[140] The implication for human disease is that obesity creates risk for lymphedema that can be ascribed to impaired baseline lymphatic clearance and heightened propensity to inflammation in response to injury. Of note here is the fact that increases in circulating exosomal platelet factor 4, a recently identified biomarker, are characteristic of various forms of lymphatic vascular dysfunction, including lipedema, another fat disorder associated with abnormal lymphatic function,[141–144] but not of those with exogenous obesity in the absence of a defined lymphatic disorder.[145] The mechanistic role of platelet factor 4 is not yet defined, but may relate to the specific inflammatory signature of lymphatic dysfunction and its relationship to the adipose response.

These ongoing observations are certainly important for the evaluation and management of human lymphedema, but the broader implications include the idea that human obesity might be modulated by the influences of lymphatic vasculature and function, suggesting that future therapeutic approaches might entail the promotion of lymphatic endothelial integrity or functionally interfering with lymphatic adipogenic influences.[146]

LYMPHATIC DISEASES AND THEIR COMORBIDITIES

The last decade of research into lymphedema and the lymphatic vasculature has led to an explosion of insights into the relationship between the presence of disease and the loss of lymphatic functional integrity. A large and ever-expanding list of pathological states is now associated with the presence of abnormal structure or function of the lymphatic circulation, either regionally or systemically. This pathological array comprises hypertension,[147–149] atherosclerosis and dyslipidemia,[150–152] and myocardial infarction and congestive heart failure,[153–155] as well as inflammatory bowel disease[156,157] and neurodegenerative disorders.[158–161]

Such findings dramatically broaden the scope of current and future lymphatic investigation and the clinical approach to patients with lymphedema. Today, the clinician must be sensitive, not only to the complexity and impact of lymphedema upon the health and well-being of the patient, but also to the broad spectrum of health and disease that might be inferred from the presence of a lymphedema diagnosis. In future, our continued investigative successes will undoubtedly provide newer and more sensitive biomarkers that will help to uncover the interrelationships among lymphedema, obesity, and a broad array of human pathology.

ARTICLE INFORMATION

Affiliation

Allan and Tina Neill Professor of Lymphatic Research and Medicine, Stanford University School of Medicine, Stanford, CA.

Disclosures

Dr Rockson has received grant support from the following commercial entities: Eiger Pharmaceuticals, Inc and Fibralign, Inc. Dr Rockson serves as the Chief Medical Officer for Koya, Inc.

REFERENCES

1. Rockson SG. Lymphatic medicine: paradoxically and unnecessarily ignored. *Lymphat Res Biol.* 2017;15:315–316. doi: 10.1089/lrb.2017.29033.sr
2. Rockson SG. Lymphedema after breast cancer treatment. *N Engl J Med.* 2018;379:1937–1944. doi: 10.1056/NEJMcp1803290
3. Rockson SG. LIMPRINT: elucidating the global problem of lymphedema. *Lymphat Res Biol.* 2019;17:119–120. doi: 10.1089/lrb.2019.29062.sr
4. Rockson SG, Keeley V, Kilbreath S, Szuba A, Towers A. Cancer-associated secondary lymphoedema. *Nat Rev Dis Primers.* 2019;5:22. doi: 10.1038/s41572-019-0072-5
5. Rockson SG, Rivera KK. Estimating the population burden of lymphedema. *Ann N Y Acad Sci.* 2008;1131:147–154. doi: 10.1196/annals.1413.014
6. Rockson SG. Secondary lymphedema: is it a primary disease? *Lymphat Res Biol.* 2008;6:63–64. doi: 10.1089/lrb.2008.6201
7. Leppanen VM, Brouillard P, Korhonen EA, Sipila T, Jha SK, Revencu N, Labarque V, Fastre E, Schlogel M, Ravoet M, et al. Characterization of ANGPT2 mutations associated with primary lymphedema. *Sci Transl Med.* 2020;12:eaax8013.

Downloaded from http://ahajournals.org by on December 4, 2024

8. Martin-Almedina S, Mortimer P, Ostergaard P. Development and physiological functions of the lymphatic system - insights from genetic studies of lymphedema [published online ahead of print January 28, 2021]. *Physiol Rev*. doi: 10.1152/physrev.00006.2020
9. Ferrell RE, Levinson KL, Esman JH, Kimak MA, Lawrence EC, Barmada MM, Finegold DN. Hereditary lymphedema: evidence for linkage and genetic heterogeneity. *Hum Mol Genet*. 1998;7:2073–2078. doi: 10.1093/hmg/7.13.2073
10. Gordon K, Schulte D, Brice G, Simpson MA, Roukens MG, van Impel A, Connell F, Kalidas K, Jeffery S, Mortimer PS, et al. Mutation in vascular endothelial growth factor-C, a ligand for vascular endothelial growth factor receptor-3, is associated with autosomal dominant milroy-like primary lymphedema. *Circ Res*. 2013;112:956–960. doi: 10.1161/CIRCRESAHA.113.300350
11. Nadarajah N, Schulte D, McConnell V, Martin-Almedina S, Karapouliou C, Mortimer PS, Jeffery S, Schulte-Merker S, Gordon K, Mansour S, et al. A novel splice-site mutation in VEGFC is associated with congenital primary lymphoedema of gordon. *Int J Mol Sci*. 2018;19:2259.
12. Alders M, Hogan BM, Gjini E, Salehi F, Al-Gazali L, Hennekam EA, Holmberg EE, Mannens MM, Mulder MF, Offerhaus GJ, et al. Mutations in CCBE1 cause generalized lymph vessel dysplasia in humans. *Nat Genet*. 2009;41:1272–1274. doi: 10.1038/ng.484
13. Scheuerle AE, Sweed NT, Timmons CF, Smith ED, Alcaraz WA, Shinde DN. An additional case of Hennekam lymphangiectasia-lymphedema syndrome caused by loss-of-function mutation in ADAMTS3. *Am J Med Genet A*. 2018;176:2858–2861. doi: 10.1002/ajmg.a.40633
14. Kazenwadel J, Betterman KL, Chong CE, Stokes PH, Lee YK, Secker GA, Agalarov Y, Demir CS, Lawrence DM, Sutton DL, et al. GATA2 is required for lymphatic vessel valve development and maintenance. *J Clin Invest*. 2015;125:2979–2994. doi: 10.1172/JCI78888
15. Lyons O, Saha P, Seet C, Kuchta A, Arnold A, Grover S, Rashbrook V, Sabine A, Vizcay-Barrena G, Patel A, et al. Human venous valve disease caused by mutations in FOXC2 and GJC2. *J Exp Med*. 2017;214:2437–2452. doi: 10.1084/jem.20160875
16. Li D, Wenger TL, Seiler C, March ME, Gutierrez-Uzquiza A, Kao C, Bhoj E, Tian L, Rosenbach M, Liu Y, et al. Pathogenic variant in EPHB4 results in central conducting lymphatic anomaly. *Hum Mol Genet*. 2018;27:3233–3245. doi: 10.1093/hmg/ddy218
17. Sarica M, Gordon K, van Zanten M, Heenan SD, Mortimer PS, Irwin AG, Ramachandra V, Ostergaard P, Mansour S. Lymphoscintigraphic abnormalities associated with milroy disease and lymphedema-distichiasis syndrome. *Lymphat Res Biol*. 2019;17:610–619. doi: 10.1089/lrb.2019.0016
18. Choi D, Park E, Jung E, Cha B, Lee S, Yu J, Kim PM, Lee S, Hong YJ, Koh CJ, et al. Piezo1 incorporates mechanical force signals into the genetic program that governs lymphatic valve development and maintenance. *JCI Insight*. 2019;4:e125068.
19. Betterman KL, Sutton DL, Secker GA, Kazenwadel J, Oszmiana A, Lim L, Miura N, Sorokin L, Hogan BM, Kahn ML, et al. Atypical cadherin FAT4 orchestrates lymphatic endothelial cell polarity in response to flow. *J Clin Invest*. 2020;130:3315–3328. doi: 10.1172/JCI99027
20. Gordon K, Mortimer PS, van Zanten M, Jeffery S, Ostergaard P, Mansour S. The St George's classification algorithm of primary lymphatic anomalies. *Lymphat Res Biol*. 2021;19:25–30. doi: 10.1089/lrb.2020.0104
21. Munn LL, Padera TP. Imaging the lymphatic system. *Microvasc Res*. 2014;96:55–63. doi: 10.1016/j.mvr.2014.06.006
22. Polomska AK, Proulx ST. Imaging technology of the lymphatic system. *Adv Drug Deliv Rev*. 2021;170:294–311. doi: 10.1016/j.addr.2020.08.013
23. Szuba A, Shin WS, Strauss HW, Rockson S. The third circulation: radionuclide lymphoscintigraphy in the evaluation of lymphedema. *J Nucl Med*. 2003;44:43–57.
24. Hassanein AH, Maclellan RA, Grant FD, Greene AK. Diagnostic accuracy of lymphoscintigraphy for lymphedema and analysis of false-negative tests. *Plast Reconstr Surg Glob Open*. 2017;5:e1396. doi: 10.1097/GOX.0000000000001396
25. Pappalardo M, Cheng MH. Lymphoscintigraphy for the diagnosis of extremity lymphedema: current controversies regarding protocol, interpretation, and clinical application. *J Surg Oncol*. 2020;121:37–47. doi: 10.1002/jso.25526
26. Iimura T, Fukushima Y, Kumita S, Ogawa R, Hyakusoku H. Estimating lymphodynamic conditions and lymphovenous anastomosis efficacy using (99m)Tc-phytate lymphoscintigraphy with SPECT-CT in patients with lower-limb lymphedema. *Plast Reconstr Surg Glob Open*. 2015;3:e404. doi: 10.1097/GOX.0000000000000375
27. Shin SU, Lee W, Park EA, Shin CI, Chung JW, Park JH. Comparison of characteristic CT findings of lymphedema, cellulitis, and generalized edema in lower leg swelling. *Int J Cardiovasc Imaging*. 2013;29(suppl 2):135–143. doi: 10.1007/s10554-013-0332-5
28. Rockson SG. A role for near infrared fluorescent imaging in the evaluation of lymphatic function. *Lymphat Res Biol*. 2017;15:203. doi: 10.1089/lrb.2017.29031.sr
29. Chong C, Scholkmann F, Bachmann SB, Luciani P, Leroux JC, Detmar M, Proulx ST. In vivo visualization and quantification of collecting lymphatic vessel contractility using near-infrared imaging. *Sci Rep*. 2016;6:22930. doi: 10.1038/srep22930
30. Groenlund JH, Telinius N, Skov SN, Hjortdal V. A validation study of near-infrared fluorescence imaging of lymphatic vessels in humans. *Lymphat Res Biol*. 2017;15:227–234. doi: 10.1089/lrb.2016.0061
31. Kelly B, Mohanakumar S, Telinius N, Alstrup M, Hjortdal V. Function of upper extremity human lymphatics assessed by near-infrared fluorescence imaging. *Lymphat Res Biol*. 2020;18:226–231. doi: 10.1089/lrb.2019.0041
32. Granoff MD, Johnson AR, Lee BT, Padera TP, Bouta EM, Singhal D. A novel approach to quantifying lymphatic contractility during indocyanine green lymphangiography. *Plast Reconstr Surg*. 2019;144:1197–1201. doi: 10.1097/PRS.0000000000006176
33. Akita S, Nakamura R, Yamamoto N, Tokumoto H, Ishigaki T, Yamaji Y, Sasahara Y, Kubota Y, Mitsukawa N, Satoh K. Early detection of lymphatic disorder and treatment for lymphedema following breast cancer. *Plast Reconstr Surg*. 2016;138:192e–202e.
34. Narushima M, Yamamoto T, Ogata F, Yoshimatsu H, Mihara M, Koshima I. Indocyanine green lymphography findings in limb lymphedema. *J Reconstr Microsurg*. 2016;32:72–79. doi: 10.1055/s-0035-1564608
35. Yoon JA, Shin MJ, Kim JH. Indocyanine green lymphography and lymphoscintigraphy severity stage showed strong correlation in lower limb lymphedema. *Lymphat Res Biol*. 2021;19:80–85. doi: 10.1089/lrb.2020.0043
36. Akita S, Unno N, Maegawa J, Kimata Y, Fukamizu H, Yabuki Y, Shinaoka A, Sano M, Kawasaki Y, Fujiwara T, et al. HAMAMATSU-ICG study: protocol for a phase III, multicentre, single-arm study to assess the usefulness of indocyanine green fluorescent lymphography in assessing secondary lymphoedema. *Contemp Clin Trials Commun*. 2020;19:100595. doi: 10.1016/j.conctc.2020.100595
37. Garza RM, Chang DW. Lymphovenous bypass for the treatment of lymphedema. *J Surg Oncol*. 2018;118:743–749. doi: 10.1002/jso.25166
38. Hara H, Mihara M. Multi-area lymphaticovenous anastomosis with multi-lymphosome injection in indocyanine green lymphography: a prospective study. *Microsurgery*. 2019;39:167–173. doi: 10.1002/micr.30398
39. Yamamoto T, Yoshimatsu H, Yamamoto N. Complete lymph flow reconstruction: a free vascularized lymph node true perforator flap transfer with efferent lymphaticolymphatic anastomosis. *J Plast Reconstr Aesthet Surg*. 2016;69:1227–1233. doi: 10.1016/j.bjps.2016.06.028
40. Koelmeyer LA, Thompson BM, Mackie H, Blackwell R, Heydon-White A, Moloney E, Gaitatzis K, Boyages J, Suami H. Personalizing conservative lymphedema management using indocyanine green-guided manual lymphatic drainage. *Lymphat Res Biol*. 2021;19:56–65. doi: 10.1089/lrb.2020.0090
41. Proulx ST, Luciani P, Derzsi S, Rinderknecht M, Mumprecht V, Leroux JC, Detmar M. Quantitative imaging of lymphatic function with liposomal indocyanine green. *Cancer Res*. 2010;70:7053–7062. doi: 10.1158/0008-5472.CAN-10-0271
42. Kraft JC, Treuting PM, Ho RJY. Indocyanine green nanoparticles undergo selective lymphatic uptake, distribution and retention and enable detailed mapping of lymph vessels, nodes and abnormalities. *J Drug Target*. 2018;26:494–504. doi: 10.1080/1061186X.2018.1433681
43. Yu DX, Ma XX, Wang Q, Zhang Y, Li CF. Morphological changes of the thoracic duct and accessory lymphatic channels in patients with chylothorax: detection with unenhanced magnetic resonance imaging. *Eur Radiol*. 2013;23:702–711. doi: 10.1007/s00330-012-2642-8
44. Kim EY, Hwang HS, Lee HY, Cho JH, Kim HK, Lee KS, Shim YM, Zo J. Anatomic and functional evaluation of central lymphatics with noninvasive magnetic resonance lymphangiography. *Medicine (Baltimore)*. 2016;95:e3109. doi: 10.1097/MD.0000000000003109
45. Arrivé L, Derhy S, El Mouhadi S, Monnier-Cholley L, Menu Y, Becker C. Noncontrast magnetic resonance lymphography. *J Reconstr Microsurg*. 2016;32:80–86. doi: 10.1055/s-0035-1549133
46. Cellina M, Oliva G, Menozzi A, Soresina M, Martinenghi C, Gibelli D. Noncontrast Magnetic Resonance Lymphangiography: an emerging technique for the study of lymphedema. *Clin Imaging*. 2019;53:126–133. doi: 10.1016/j.clinimag.2018.10.006
47. Arrivé L, Derhy S, Dlimi C, El Mouhadi S, Monnier-Cholley L, Becker C. Noncontrast magnetic resonance lymphography for evaluation of lymph

Downloaded from http://ahajournals.org by on December 4, 2024

node transfer for secondary upper limb lymphedema. *Plast Reconstr Surg*. 2017;140:806e–811e. doi: 10.1097/PRS.0000000000003862
48. Mitsumori LM, McDonald ES, Neligan PC, Maki JH. Peripheral magnetic resonance lymphangiography: techniques and applications. *Tech Vasc Interv Radiol*. 2016;19:262–272. doi: 10.1053/j.tvir.2016.10.007
49. Mazzei MA, Gentili F, Mazzei FG, Gennaro P, Guerrieri D, Nigri A, Gabriele G, Weber E, Fausto A, Botta G, et al. High-resolution MR lymphangiography for planning lymphaticovenous anastomosis treatment: a single-centre experience. *Radiol Med*. 2017;122:918–927. doi: 10.1007/s11547-017-0795-x
50. Neligan PC, Kung TA, Maki JH. MR lymphangiography in the treatment of lymphedema. *J Surg Oncol*. 2017;115:18–22. doi: 10.1002/jso.24337
51. Zeltzer AA, Brussaard C, Koning M, De Baerdemaeker R, Hendrickx B, Hamdi M, de Mey J. MR lymphography in patients with upper limb lymphedema: the GPS for feasibility and surgical planning for lympho-venous bypass. *J Surg Oncol*. 2018;118:407–415. doi: 10.1002/jso.25145
52. Pimpalwar S, Chinnadurai P, Chau A, Pereyra M, Ashton D, Masand P, Krishnamurthy R, Jadhav S. Dynamic contrast enhanced magnetic resonance lymphangiography: categorization of imaging findings and correlation with patient management. *Eur J Radiol*. 2018;101:129–135. doi: 10.1016/j.ejrad.2018.02.021
53. Itkin M, Nadolski GJ. Modern techniques of lymphangiography and interventions: current status and future development. *Cardiovasc Intervent Radiol*. 2018;41:366–376. doi: 10.1007/s00270-017-1863-2
54. Iker E, Mayfield CK, Gould DJ, Patel KM. Characterizing lower extremity lymphedema and lipedema with cutaneous ultrasonography and an objective computer-assisted measurement of dermal echogenicity. *Lymphat Res Biol*. 2019;17:525–530. doi: 10.1089/lrb.2017.0090
55. Bianchi A, Visconti G, Hayashi A, Santoro A, Longo V, Salgarello M. Ultra-High frequency ultrasound imaging of lymphatic channels correlates with their histological features: a step forward in lymphatic surgery. *J Plast Reconstr Aesthet Surg*. 2020;73:1622–1629. doi: 10.1016/j.bjps.2020.05.053
56. Thompson M, Korourian S, Henry-Tillman R, Adkins L, Mumford S, Westbrook KC, Klimberg VS. Axillary reverse mapping (ARM): a new concept to identify and enhance lymphatic preservation. *Ann Surg Oncol*. 2007;14:1890–1895. doi: 10.1245/s10434-007-9412-x
57. Tummel E, Ochoa D, Korourian S, Betzold R, Adkins L, McCarthy M, Hung S, Kalkwarf K, Gallagher K, Lee JY, et al. Does axillary reverse mapping prevent lymphedema after lymphadenectomy? *Ann Surg*. 2017;265:987–992. doi: 10.1097/SLA.0000000000001778
58. Yue T, Zhuang D, Zhou P, Zheng L, Fan Z, Zhu J, Hou L, Yu F, Dong X, Xiao L, et al. A prospective study to assess the feasibility of axillary reverse mapping and evaluate its effect on preventing lymphedema in breast cancer patients. *Clin Breast Cancer*. 2015;15:301–306. doi: 10.1016/j.clbc.2015.01.010
59. Han C, Yang B, Zuo WS, Zheng G, Yang L, Zheng MZ. The feasibility and oncological safety of axillary reverse mapping in patients with breast cancer: a systematic review and meta-analysis of prospective studies. *PLoS One*. 2016;11:e0150285. doi: 10.1371/journal.pone.0150285
60. Klimberg S. Axillary reverse mapping in preventing lymphedema in patients with breast cancer undergoing axillary lymph node dissection. 2021. Accessed February 2021. https://clinicaltrials.gov/ct2/show/NCT03927027
61. Boccardo F, Casabona F, De Cian F, DeCian F, Friedman D, Murelli F, Puglisi M, Campisi CC, Molinari L, Spinaci S, et al. Lymphatic microsurgical preventing healing approach (LYMPHA) for primary surgical prevention of breast cancer-related lymphedema: over 4 years follow-up. *Microsurgery*. 2014;34:421–424. doi: 10.1002/micr.22254
62. Feldman S, Bansil H, Ascherman J, Grant R, Borden B, Henderson P, Ojo A, Taback B, Chen M, Ananthakrishnan P, et al. Single institution experience with lymphatic microsurgical preventive healing approach (LYMPHA) for the primary prevention of lymphedema. *Ann Surg Oncol*. 2015;22:3296–3301. doi: 10.1245/s10434-015-4721-y
63. Ozmen T, Lazaro M, Zhou Y, Vinyard A, Avisar E. Evaluation of simplified lymphatic microsurgical preventing healing approach (S-LYMPHA) for the prevention of breast cancer-related clinical lymphedema after axillary lymph node dissection. *Ann Surg*. 2019;270:1156–1160. doi: 10.1097/SLA.0000000000002827
64. Brorson H, Svensson H. Liposuction combined with controlled compression therapy reduces arm lymphedema more effectively than controlled compression therapy alone. *Plast Reconstr Surg*. 1998;102:1058–1067; discussion 1068.
65. Brorson H. Liposuction in lymphedema treatment. *J Reconstr Microsurg*. 2016;32:56–65. doi: 10.1055/s-0035-1549158
66. Lee D, Piller N, Hoffner M, Manjer J, Brorson H. Liposuction of postmastectomy arm lymphedema decreases the incidence of erysipelas. *Lymphology*. 2016;49:85–92.
67. Granzow JW. Lymphedema surgery: the current state of the art. *Clin Exp Metastasis*. 2018;35:553–558. doi: 10.1007/s10585-018-9897-7
68. Schaverien MV, Munnoch DA, Brorson H. Liposuction treatment of lymphedema. *Semin Plast Surg*. 2018;32:42–47. doi: 10.1055/s-0038-1635116
69. Silva AK, Chang DW. Vascularized lymph node transfer and lymphovenous bypass: novel treatment strategies for symptomatic lymphedema. *J Surg Oncol*. 2016;113:932–939. doi: 10.1002/jso.24171
70. Yamamoto T, Narushima M, Yoshimatsu H, Seki Y, Yamamoto N, Oka A, Hara H, Koshima I. Minimally invasive lymphatic supermicrosurgery (MILS): indocyanine green lymphography-guided simultaneous multisite lymphaticovenular anastomoses via millimeter skin incisions. *Ann Plast Surg*. 2014;72:67–70. doi: 10.1097/SAP.0b013e3182605580
71. Shih HB, Shakir A, Nguyen DH. Use of indocyanine green-SPY angiography for tracking lymphatic recovery after lymphaticovenous anastomosis. *Ann Plast Surg*. 2016;76(suppl 3):S232–S237. doi: 10.1097/SAP.0000000000000766
72. Allen RJ Jr, Cheng MH. Lymphedema surgery: patient selection and an overview of surgical techniques. *J Surg Oncol*. 2016;113:923–931. doi: 10.1002/jso.24170
73. Cheng MH, Loh CYY, Lin CY. Outcomes of vascularized lymph node transfer and lymphovenous anastomosis for treatment of primary lymphedema. *Plast Reconstr Surg Glob Open*. 2018;6:e2056. doi: 10.1097/GOX.0000000000002056
74. Rosian K, Stanak M. Efficacy and safety assessment of lymphovenous anastomosis in patients with primary and secondary lymphoedema: a systematic review of prospective evidence. *Microsurgery*. 2019;39:763–772. doi: 10.1002/micr.30514
75. Chang DW, Suami H, Skoracki R. A prospective analysis of 100 consecutive lymphovenous bypass cases for treatment of extremity lymphedema. *Plast Reconstr Surg*. 2013;132:1305–1314. doi: 10.1097/PRS.0b013e3182a4d626
76. Cornelissen AJM, Beugels J, Ewalds L, Heuts EM, Keuter XHA, Piatkowski A, van der Hulst R, Qiu Shao SS. The effect of lymphaticovenous anastomosis in breast cancer-related lymphedema: a review of the literature. *Lymphat Res Biol*. 2018;16:426–434.
77. Wolfs JAGN, de Joode LGEH, van der Hulst RRWJ, Qiu SS. Correlation between patency and clinical improvement after lymphaticovenous anastomosis (LVA) in breast cancer-related lymphedema: 12-month follow-up. *Breast Cancer Res Treat*. 2020;179:131–138. doi: 10.1007/s10549-019-05450-2
78. Basta MN, Gao LL, Wu LC. Operative treatment of peripheral lymphedema: a systematic meta-analysis of the efficacy and safety of lymphovenous microsurgery and tissue transplantation. *Plast Reconstr Surg*. 2014;133:905–913. doi: 10.1097/PRS.0000000000000010
79. Schaverien MV, Badash I, Patel KM, Selber JC, Cheng MH. Vascularized lymph node transfer for lymphedema. *Semin Plast Surg*. 2018;32:28–35. doi: 10.1055/s-0038-1632401
80. Nguyen AT, Suami H, Hanasono MM, Womack VA, Wong FC, Chang EI. Long-term outcomes of the minimally invasive free vascularized omental lymphatic flap for the treatment of lymphedema. *J Surg Oncol*. 2017;115:84–89. doi: 10.1002/jso.24379
81. Schaverien MV, Hofstetter WL, Selber JC. Vascularized jejunal mesenteric lymph node transfer for lymphedema: a novel approach. *Plast Reconstr Surg*. 2018;141:468e–469e. doi: 10.1097/PRS.0000000000004162
82. Cheng MH, Huang JJ, Huang JJ, Nguyen DH, Saint-Cyr M, Zenn MR, Tan BK, Lee CL. A novel approach to the treatment of lower extremity lymphedema by transferring a vascularized submental lymph node flap to the ankle. *Gynecol Oncol*. 2012;126:93–98. doi: 10.1016/j.ygyno.2012.04.017
83. Suami H, Scaglioni MF, Dixon KA, Tailor RC. Interaction between vascularized lymph node transfer and recipient lymphatics after lymph node dissection-a pilot study in a canine model. *J Surg Res*. 2016;204:418–427. doi: 10.1016/j.jss.2016.05.029
84. Liu HL, Pang SY, Lee CC, Wong MM, Chung HP, Chan YW. Orthotopic transfer of vascularized groin lymph node flap in the treatment of breast cancer-related lymphedema: clinical results, lymphoscintigraphy findings, and proposed mechanism. *J Plast Reconstr Aesthet Surg*. 2018;71:1033–1040. doi: 10.1016/j.bjps.2018.02.015
85. Lähteenvuo M, Honkonen K, Tervala T, Tammela T, Suominen E, Lähteenvuo J, Kholová I, Alitalo K, Ylä-Herttuala S, Saaristo A. Growth factor

Downloaded from http://ahajournals.org by on December 4, 2024

therapy and autologous lymph node transfer in lymphedema. *Circulation*. 2011;123:613–620. doi: 10.1161/CIRCULATIONAHA.110.965384
86. Dionyssiou D, Demiri E, Tsimponis A, Sarafis A, Mpalaris V, Tatsidou G, Arsos G. A randomized control study of treating secondary stage II breast cancer-related lymphoedema with free lymph node transfer. *Breast Cancer Res Treat*. 2016;156:73–79. doi: 10.1007/s10549-016-3716-0
87. Markkula SP, Leung N, Allen VB, Furniss D. Surgical interventions for the prevention or treatment of lymphoedema after breast cancer treatment. *Cochrane Database Syst Rev*. 2019;2:CD011433. doi: 10.1002/14651858.CD011433.pub2
88. Saaristo AM, Niemi TS, Viitanen TP, Tervala TV, Hartiala P, Suominen EA. Microvascular breast reconstruction and lymph node transfer for postmastectomy lymphedema patients. *Ann Surg*. 2012;255:468–473. doi: 10.1097/SLA.0b013e3182426757
89. Dayan JH, Dayan E, Smith ML. Reverse lymphatic mapping: a new technique for maximizing safety in vascularized lymph node transfer. *Plast Reconstr Surg*. 2015;135:277–285. doi: 10.1097/PRS.0000000000000822
90. Szuba A, Skobe M, Karkkainen MJ, Shin WS, Beynet DP, Rockson NB, Dakhil N, Spilman S, Goris ML, Strauss HW, et al. Therapeutic lymphangiogenesis with human recombinant VEGF-C. *FASEB J*. 2002;16:1985–1987. doi: 10.1096/fj.02-0401fje
91. Eppler SM, Combs DL, Henry TD, Lopez JJ, Ellis SG, Yi JH, Annex BH, McCluskey ER, Zioncheck TF. A target-mediated model to describe the pharmacokinetics and hemodynamic effects of recombinant human vascular endothelial growth factor in humans. *Clin Pharmacol Ther*. 2002;72:20–32. doi: 10.1067/mcp.2002.126179
92. Fritz-Six KL, Dunworth WP, Li M, Caron KM. Adrenomedullin signaling is necessary for murine lymphatic vascular development. *J Clin Invest*. 2008;118:40–50. doi: 10.1172/JCI33302
93. Dunworth WP, Fritz-Six KL, Caron KM. Adrenomedullin stabilizes the lymphatic endothelial barrier in vitro and in vivo. *Peptides*. 2008;29:2243–2249. doi: 10.1016/j.peptides.2008.09.009
94. Jin D, Harada K, Ohnishi S, Yamahara K, Kangawa K, Nagaya N. Adrenomedullin induces lymphangiogenesis and ameliorates secondary lymphoedema. *Cardiovasc Res*. 2008;80:339–345. doi: 10.1093/cvr/cvn228
95. Jin DP, An A, Liu J, Nakamura K, Rockson SG. Therapeutic responses to exogenous VEGF-C administration in experimental lymphedema: immunohistochemical and molecular characterization. *Lymphat Res Biol*. 2009;7:47–57. doi: 10.1089/lrb.2009.0002
96. Baker A, Kim H, Semple JL, Dumont D, Shoichet M, Tobbia D, Johnston M. Experimental assessment of pro-lymphangiogenic growth factors in the treatment of post-surgical lymphedema following lymphadenectomy. *Breast Cancer Res*. 2010;12:R70. doi: 10.1186/bcr2638
97. Choi I, Lee S, Kyoung Chung H, Suk Lee Y, Eui Kim K, Choi D, Park EK, Yang D, Ecoiffier T, Monahan J, et al. 9-cis retinoic acid promotes lymphangiogenesis and enhances lymphatic vessel regeneration: therapeutic implications of 9-cis retinoic acid for secondary lymphedema. *Circulation*. 2012;125:872–882. doi: 10.1161/CIRCULATIONAHA.111.030296
98. Marino D, Angehrn Y, Klein S, Riccardi S, Baenziger-Tobler N, Otto VI, Pittelkow M, Detmar M. Activation of the epidermal growth factor receptor promotes lymphangiogenesis in the skin. *J Dermatol Sci*. 2013;71:184–194. doi: 10.1016/j.jdermsci.2013.04.024
99. Goldman J, Le TX, Skobe M, Swartz MA. Overexpression of VEGF-C causes transient lymphatic hyperplasia but not increased lymphangiogenesis in regenerating skin. *Circ Res*. 2005;96:1193–1199. doi: 10.1161/01.RES.0000168918.27576.78
100. Gousopoulos E, Proulx ST, Bachmann SB, Dieterich LC, Scholl J, Karaman S, Bianchi R, Detmar M. An important role of VEGF-C in promoting lymphedema development. *J Invest Dermatol*. 2017;137:1995–2004. doi: 10.1016/j.jid.2017.04.033
101. Hartiala P, Saarikko AM. Lymphangiogenesis and lymphangiogenic growth factors. *J Reconstr Microsurg*. 2016;32:10–15. doi: 10.1055/s-0035-1544179
102. Hartiala P, Suominen S, Suominen E, Kaartinen I, Kiiski J, Viitanen T, Alitalo K, Saarikko AM. Phase 1 lymfactin® study: short-term safety of combined adenoviral VEGF-C and lymph node transfer treatment for upper extremity lymphedema. *J Plast Reconstr Aesthet Surg*. 2020;73:1612–1621. doi: 10.1016/j.bjps.2020.05.009
103. Hou C, Wu X, Jin X. Autologous bone marrow stromal cells transplantation for the treatment of secondary arm lymphedema: a prospective controlled study in patients with breast cancer related lymphedema. *Jpn J Clin Oncol*. 2008;38:670–674. doi: 10.1093/jjco/hyn090
104. Maldonado GE, Pérez CA, Covarrubias EE, Cabriales SA, Leyva LA, Pérez JC, Almaguer DG. Autologous stem cells for the treatment of post-mastectomy lymphedema: a pilot study. *Cytotherapy*. 2011;13:1249–1255. doi: 10.3109/14653249.2011.594791
105. Toyserkani NM, Jensen CH, Sheikh SP, Sørensen JA. Cell-assisted lipotransfer using autologous adipose-derived stromal cells for alleviation of breast cancer-related lymphedema. *Stem Cells Transl Med*. 2016;5:857–859. doi: 10.5966/sctm.2015-0357
106. Conrad C, Niess H, Huss R, Huber S, von Luettichau I, Nelson PJ, Ott HC, Jauch KW, Bruns CJ. Multipotent mesenchymal stem cells acquire a lymphendothelial phenotype and enhance lymphatic regeneration in vivo. *Circulation*. 2009;119:281–289. doi: 10.1161/CIRCULATIONAHA.108.793208
107. Jiang X, Nicolls MR, Tian W, Rockson SG. Lymphatic dysfunction, leukotrienes, and lymphedema. *Annu Rev Physiol*. 2018;80:49–70. doi: 10.1146/annurev-physiol-022516-034008
108. Zampell JC, Yan A, Elhadad S, Avraham T, Weitman E, Mehrara BJ. CD4(+) cells regulate fibrosis and lymphangiogenesis in response to lymphatic fluid stasis. *PLoS One*. 2012;7:e49940. doi: 10.1371/journal.pone.0049940
109. Tabibiazar R, Cheung L, Han J, Swanson J, Beilhack A, An A, Dadras SS, Rockson N, Joshi S, Wagner R, et al. Inflammatory manifestations of experimental lymphatic insufficiency. *PLoS Med*. 2006;3:e254. doi: 10.1371/journal.pmed.0030254
110. Nakamura K, Radhakrishnan K, Wong YM, Rockson SG. Anti-inflammatory pharmacotherapy with ketoprofen ameliorates experimental lymphatic vascular insufficiency in mice. *PLoS One*. 2009;4:e8380. doi: 10.1371/journal.pone.0008380
111. Rockson SG, Tian W, Jiang X, Kuznetsova T, Haddad F, Zampell J, Mehrara B, Sampson JP, Roche L, Kim J, et al. Pilot studies demonstrate the potential benefits of antiinflammatory therapy in human lymphedema. *JCI Insight*. 2018;3:e123775.
112. Tian W, Rockson SG, Jiang X, Kim J, Begaye A, Shuffle EM, Tu AB, Cribb M, Nepiyushchikh Z, Feroze AH, et al. Leukotriene B4 antagonism ameliorates experimental lymphedema. *Sci Transl Med*. 2017;9:eaal3920.
113. Murtomaki A, Uh MK, Kitajewski C, Zhao J, Nagasaki T, Shawber CJ, Kitajewski J. Notch signaling functions in lymphatic valve formation. *Development*. 2014;141:2446–2451. doi: 10.1242/dev.101188
114. Mihara M, Hara H, Hayashi Y, Narushima M, Yamamoto T, Todokoro T, Iida T, Sawamoto N, Araki J, Kikuchi K, et al. Pathological steps of cancer-related lymphedema: histological changes in the collecting lymphatic vessels after lymphadenectomy. *PLoS One*. 2012;7:e41126. doi: 10.1371/journal.pone.0041126
115. Gardenier JC, Kataru RP, Hespe GE, Savetsky IL, Torrisi JS, Nores GD, Jowhar DK, Nitti MD, Schofield RC, Carlow DC, et al. Topical tacrolimus for the treatment of secondary lymphedema. *Nat Commun*. 2017;8:14345. doi: 10.1038/ncomms14345
116. Avraham T, Daluvoy S, Zampell J, Yan A, Haviv YS, Rockson SG, Mehrara BJ. Blockade of transforming growth factor-beta1 accelerates lymphatic regeneration during wound repair. *Am J Pathol*. 2010;177:3202–3214. doi: 10.2353/ajpath.2010.100594
117. Avraham T, Zampell JC, Yan A, Elhadad S, Weitman ES, Rockson SG, Bromberg J, Mehrara BJ. Th2 differentiation is necessary for soft tissue fibrosis and lymphatic dysfunction resulting from lymphedema. *FASEB J*. 2013;27:1114–1126. doi: 10.1096/fj.12-222695
118. Savetsky IL, Ghanta S, Gardenier JC, Torrisi JS, García Nores GD, Hespe GE, Nitti MD, Kataru RP, Mehrara BJ. Th2 cytokines inhibit lymphangiogenesis. *PLoS One*. 2015;10:e0126908. doi: 10.1371/journal.pone.0126908
119. Shin K, Kataru RP, Park HJ, Kwon BI, Kim TW, Hong YK, Lee SH. TH2 cells and their cytokines regulate formation and function of lymphatic vessels. *Nat Commun*. 2015;6:6196. doi: 10.1038/ncomms7196
120. Gousopoulos E, Proulx ST, Bachmann SB, Scholl J, Dionyssiou D, Demiri E, Halin C, Dieterich LC, Detmar M. Regulatory T cell transfer ameliorates lymphedema and promotes lymphatic vessel function. *JCI Insight*. 2016;1:e89081. doi: 10.1172/jci.insight.89081
121. Ogata F, Fujiu K, Matsumoto S, Nakayama Y, Shibata M, Oike Y, Koshima I, Watabe T, Nagai R, Manabe I. Excess lymphangiogenesis cooperatively induced by macrophages and CD4(+) T cells drives the pathogenesis of lymphedema. *J Invest Dermatol*. 2016;136:706–714. doi: 10.1016/j.jid.2015.12.001
122. Rutkowski JM, Moya M, Johannes J, Goldman J, Swartz MA. Secondary lymphedema in the mouse tail: lymphatic hyperplasia, VEGF-C upregulation, and the protective role of MMP-9. *Microvasc Res*. 2006;72:161–171. doi: 10.1016/j.mvr.2006.05.009
123. Ghanta S, Cuzzone DA, Torrisi JS, Albano NJ, Joseph WJ, Savetsky IL, Gardenier JC, Chang D, Zampell JC, Mehrara BJ. Regulation of inflammation

Downloaded from http://ahajournals.org by on December 4, 2024

and fibrosis by macrophages in lymphedema. *Am J Physiol Heart Circ Physiol*. 2015;308:H1065–H1077. doi: 10.1152/ajpheart.00598.2014
124. Wynn TA. Fibrotic disease and the T(H)1/T(H)2 paradigm. *Nat Rev Immunol*. 2004;4:583–594. doi: 10.1038/nri1412
125. Cho S, Roh K, Park J, Park YS, Lee M, Cho S, Kil EJ, Cho MJ, Oh JS, Byun HS, et al. Hydrolysis of hyaluronic acid in lymphedematous tissue alleviates fibrogenesis via TH1 cell-mediated cytokine expression. *Sci Rep*. 2017;7:35. doi: 10.1038/s41598-017-00085-z
126. Qian J, Tian W, Jiang X, Tamosiuniene R, Sung YK, Shuffle EM, Tu AB, Valenzuela A, Jiang S, Zamanian RT, et al. Leukotriene B4 activates pulmonary artery adventitial fibroblasts in pulmonary hypertension. *Hypertension*. 2015;66:1227–1239. doi: 10.1161/HYPERTENSIONAHA.115.06370
127. Rockson SG. Precipitating factors in lymphedema: myths and realities. *Cancer*. 1998;83:2814–2816. doi: 10.1002/(sici)1097-0142(19981215)83:12b+<2814::aid-cncr31>3.3.co;2-5
128. Borri M, Gordon KD, Hughes JC, Scurr ED, Koh DM, Leach MO, Mortimer PS, Schmidt MA. Magnetic resonance imaging-based assessment of breast cancer-related lymphoedema tissue composition. *Invest Radiol*. 2017;52:554–561. doi: 10.1097/RLI.0000000000000386
129. Zampell JC, Aschen S, Weitman ES, Yan A, Elhadad S, De Brot Andrade M, Mehrara BJ. Regulation of adipogenesis by lymphatic fluid stasis: part I. Adipogenesis, fibrosis, and inflammation. *Plast Reconstr Surg*. 2012;129:825–834. doi: 10.1097/PRS.0b013e3182450b2d
130. Aschen S, Zampell JC, Elhadad S, Weitman E, De Brot Andrade M, Mehrara BJ. Regulation of adipogenesis by lymphatic fluid stasis: part II. Expression of adipose differentiation genes. *Plast Reconstr Surg*. 2012;129:838–847. doi: 10.1097/PRS.0b013e3182450b47
131. Karkkainen MJ, Saaristo A, Jussila L, Karila KA, Lawrence EC, Pajusola K, Bueler H, Eichmann A, Kauppinen R, Kettunen MI, et al. A model for gene therapy of human hereditary lymphedema. *Proc Natl Acad Sci USA*. 2001;98:12677–12682. doi: 10.1073/pnas.221449198
132. Rutkowski JM, Markhus CE, Gyenge CC, Alitalo K, Wiig H, Swartz MA. Dermal collagen and lipid deposition correlate with tissue swelling and hydraulic conductivity in murine primary lymphedema. *Am J Pathol*. 2010;176:1122–1129. doi: 10.2353/ajpath.2010.090733
133. Harvey NL, Srinivasan RS, Dillard ME, Johnson NC, Witte MH, Boyd K, Sleeman MW, Oliver G. Lymphatic vascular defects promoted by Prox1 haploinsufficiency cause adult-onset obesity. *Nat Genet*. 2005;37:1072–1081. doi: 10.1038/ng1642
134. Escobedo N, Proulx ST, Karaman S, Dillard ME, Johnson N, Detmar M, Oliver G. Restoration of lymphatic function rescues obesity in Prox1-haploinsufficient mice. *JCI Insight*. 2016;1:e85096.
135. Greene AK, Grant FD, Slavin SA. Lower-extremity lymphedema and elevated body-mass index. *N Engl J Med*. 2012;366:2136–2137. doi: 10.1056/NEJMc1201684
136. Greene AK. Diagnosis and management of obesity-induced lymphedema. *Plast Reconstr Surg*. 2016;138:111e–118e. doi: 10.1097/PRS.0000000000002258
137. Greene AK, Grant FD, Maclellan RA. Obesity-induced lymphedema nonreversible following massive weight loss. *Plast Reconstr Surg Glob Open*. 2015;3:e426. doi: 10.1097/GOX.0000000000000398
138. Greene AK, Grant FD, Slavin SA, Maclellan RA. Obesity-induced lymphedema: clinical and lymphoscintigraphic features. *Plast Reconstr Surg*. 2015;135:1715–1719. doi: 10.1097/PRS.0000000000001271
139. Blum KS, Karaman S, Proulx ST, Ochsenbein AM, Luciani P, Leroux JC, Wolfrum C, Detmar M. Chronic high-fat diet impairs collecting lymphatic vessel function in mice. *PLoS One*. 2014;9:e94713. doi: 10.1371/journal.pone.0094713
140. Savetsky IL, Torrisi JS, Cuzzone DA, Ghanta S, Albano NJ, Gardenier JC, Joseph WJ, Mehrara BJ. Obesity increases inflammation and impairs lymphatic function in a mouse model of lymphedema. *Am J Physiol Heart Circ Physiol*. 2014;307:H165–H172. doi: 10.1152/ajpheart.00244.2014
141. Wold LE, Hines EA Jr, Allen EV. Lipedema of the legs; a syndrome characterized by fat legs and edema. *Ann Intern Med*. 1951;34:1243–1250. doi: 10.7326/0003-4819-34-5-1243
142. Lohrmann C, Foeldi E, Langer M. MR imaging of the lymphatic system in patients with lipedema and lipo-lymphedema. *Microvasc Res*. 2009;77:335–339. doi: 10.1016/j.mvr.2009.01.005
143. Bilancini S, Lucchi M, Tucci S, Eleuteri P. Functional lymphatic alterations in patients suffering from lipedema. *Angiology*. 1995;46:333–339. doi: 10.1177/000331979504600408
144. Forner-Cordero I, Oliván-Sasot P, Ruiz-Llorca C, Muñoz-Langa J. Lymphoscintigraphic findings in patients with lipedema. *Rev Esp Med Nucl Imagen Mol*. 2018;37:341–348. doi: 10.1016/j.remn.2018.06.008
145. Ma W, Gil HJ, Escobedo N, Benito-Martin A, Ximenez-Embun P, Munoz J, Peinado H, Rockson SG, Oliver G. Platelet factor 4 is a biomarker for lymphatic-promoted disorders. *JCI Insight*. 2020;5:e135109.
146. Oliver G, Kipnis J, Randolph GJ, Harvey NL. The lymphatic vasculature in the 21st century: novel functional roles in homeostasis and disease. *Cell*. 2020;182:270–296. doi: 10.1016/j.cell.2020.06.039
147. Chachaj A, Puła B, Chabowski M, Grzegrzółka J, Szahidewicz-Krupska E, Karczewski M, Janczak D, Dzięgiel P, Podhorska-Okołów M, Mazur G, et al. Role of the lymphatic system in the pathogenesis of hypertension in humans. *Lymphat Res Biol*. 2018;16:140–146. doi: 10.1089/lrb.2017.0051
148. Machnik A, Neuhofer W, Jantsch J, Dahlmann A, Tammela T, Machura K, Park JK, Beck FX, Müller DN, Derer W, et al. Macrophages regulate salt-dependent volume and blood pressure by a vascular endothelial growth factor-C-dependent buffering mechanism. *Nat Med*. 2009;15:545–552. doi: 10.1038/nm.1960
149. Wiig H, Schröder A, Neuhofer W, Jantsch J, Kopp C, Karlsen TV, Boschmann M, Goss J, Bry M, Rakova N, et al. Immune cells control skin lymphatic electrolyte homeostasis and blood pressure. *J Clin Invest*. 2013;123:2803–2815. doi: 10.1172/JCI60113
150. Brakenhielm E, Alitalo K. Cardiac lymphatics in health and disease. *Nat Rev Cardiol*. 2019;16:56–68. doi: 10.1038/s41569-018-0087-8
151. Lim HY, Thiam CH, Yeo KP, Bisoendial R, Hii CS, McGrath KC, Tan KW, Heather A, Alexander JS, Angeli V. Lymphatic vessels are essential for the removal of cholesterol from peripheral tissues by SR-BI-mediated transport of HDL. *Cell Metab*. 2013;17:671–684. doi: 10.1016/j.cmet.2013.04.002
152. Martel C, Li W, Fulp B, Platt AM, Gautier EL, Westerterp M, Bittman R, Tall AR, Chen SH, Thomas MJ, et al. Lymphatic vasculature mediates macrophage reverse cholesterol transport in mice. *J Clin Invest*. 2013;123:1571–1579. doi: 10.1172/JCI63685
153. Henri O, Pouehe C, Houssari M, Galas L, Nicol L, Edwards-Lévy F, Henry JP, Dumesnil A, Boukhalfa I, Banquet S, et al. Selective stimulation of cardiac lymphangiogenesis reduces myocardial edema and fibrosis leading to improved cardiac function following myocardial infarction. *Circulation*. 2016;133:1484–97; discussion 1497. doi: 10.1161/CIRCULATIONAHA.115.020143
154. Klotz L, Norman S, Vieira JM, Masters M, Rohling M, Dubé KN, Bollini S, Matsuzaki F, Carr CA, Riley PR. Cardiac lymphatics are heterogeneous in origin and respond to injury. *Nature*. 2015;522:62–67. doi: 10.1038/nature14483
155. Vuorio T, Tirronen A, Ylä-Herttuala S. Cardiac lymphatics - A new avenue for therapeutics? *Trends Endocrinol Metab*. 2017;28:285–296. doi: 10.1016/j.tem.2016.12.002
156. Rahier JF, Dubuquoy L, Colombel JF, Jouret-Mourin A, Delos M, Ferrante M, Sokol H, Hertogh GD, Salleron J, Geboes K, et al. Decreased lymphatic vessel density is associated with postoperative endoscopic recurrence in Crohn's disease. *Inflamm Bowel Dis*. 2013;19:2084–2090. doi: 10.1097/MIB.0b013e3182971cec
157. von der Weid PY, Rehal S, Ferraz JG. Role of the lymphatic system in the pathogenesis of Crohn's disease. *Curr Opin Gastroenterol*. 2011;27:335–341. doi: 10.1097/MOG.0b013e3283476e8f
158. Da Mesquita S, Fu Z, Kipnis J. The meningeal lymphatic system: a new player in neurophysiology. *Neuron*. 2018;100:375–388. doi: 10.1016/j.neuron.2018.09.022
159. Da Mesquita S, Louveau A, Vaccari A, Smirnov I, Cornelison RC, Kingsmore KM, Contarino C, Onengut-Gumuscu S, Farber E, Raper D, et al. Functional aspects of meningeal lymphatics in ageing and Alzheimer's disease. *Nature*. 2018;560:185–191. doi: 10.1038/s41586-018-0368-8
160. Louveau A, Smirnov I, Keyes TJ, Eccles JD, Rouhani SJ, Peske JD, Derecki NC, Castle D, Mandell JW, Lee KS, et al. Structural and functional features of central nervous system lymphatic vessels. *Nature*. 2015;523:337–341. doi: 10.1038/nature14432
161. Patel TK, Habimana-Griffin L, Gao X, Xu B, Achilefu S, Alitalo K, McKee CA, Sheehan PW, Musiek ES, Xiong C, et al. Dural lymphatics regulate clearance of extracellular tau from the CNS. *Mol Neurodegener*. 2019;14:11. doi: 10.1186/s13024-019-0312-x

Downloaded from http://ahajournals.org by on December 4, 2024